

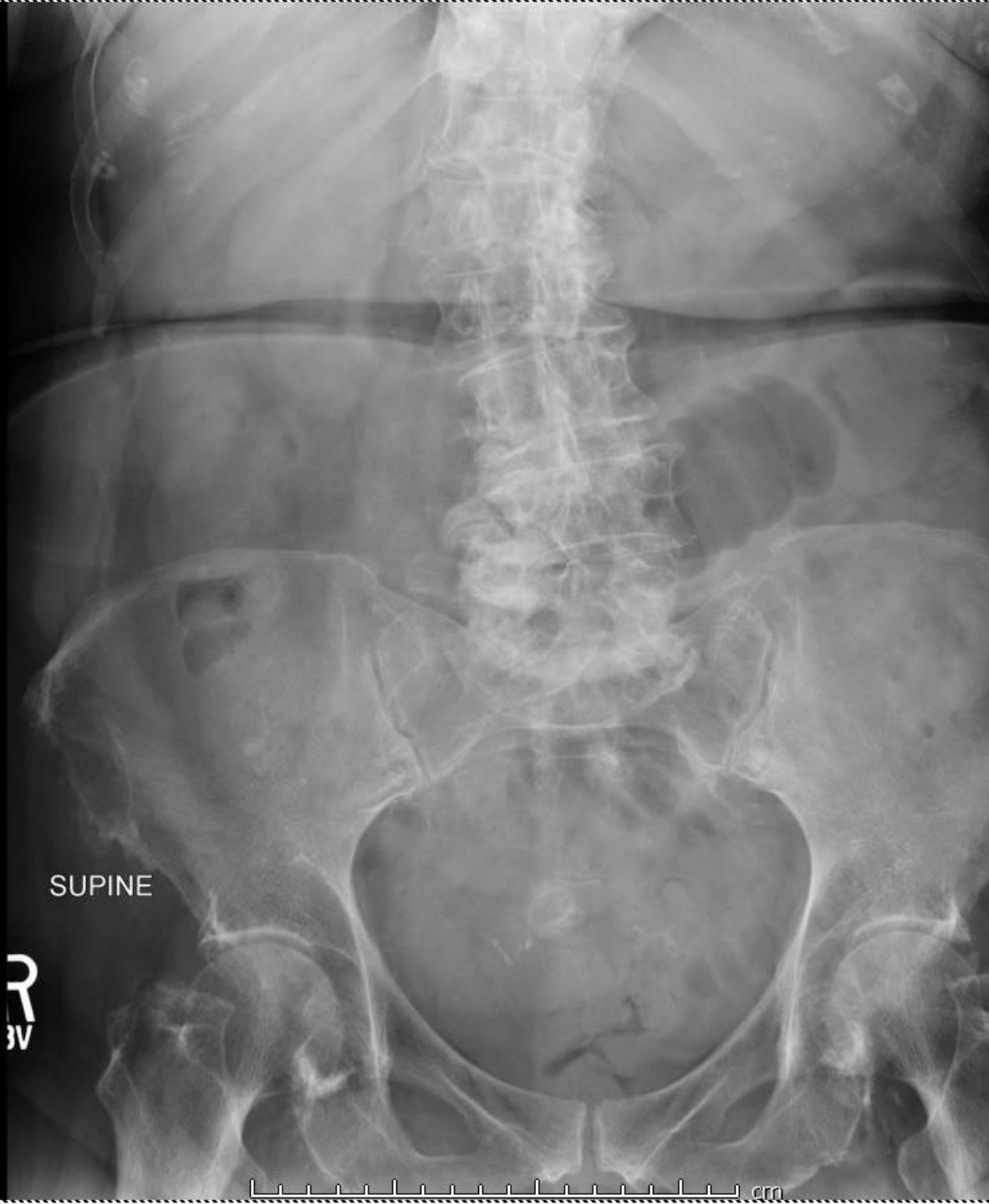Radiology Elective Case Presentation

Sophia Shimer

March 22, 2018

A case from ED radiology

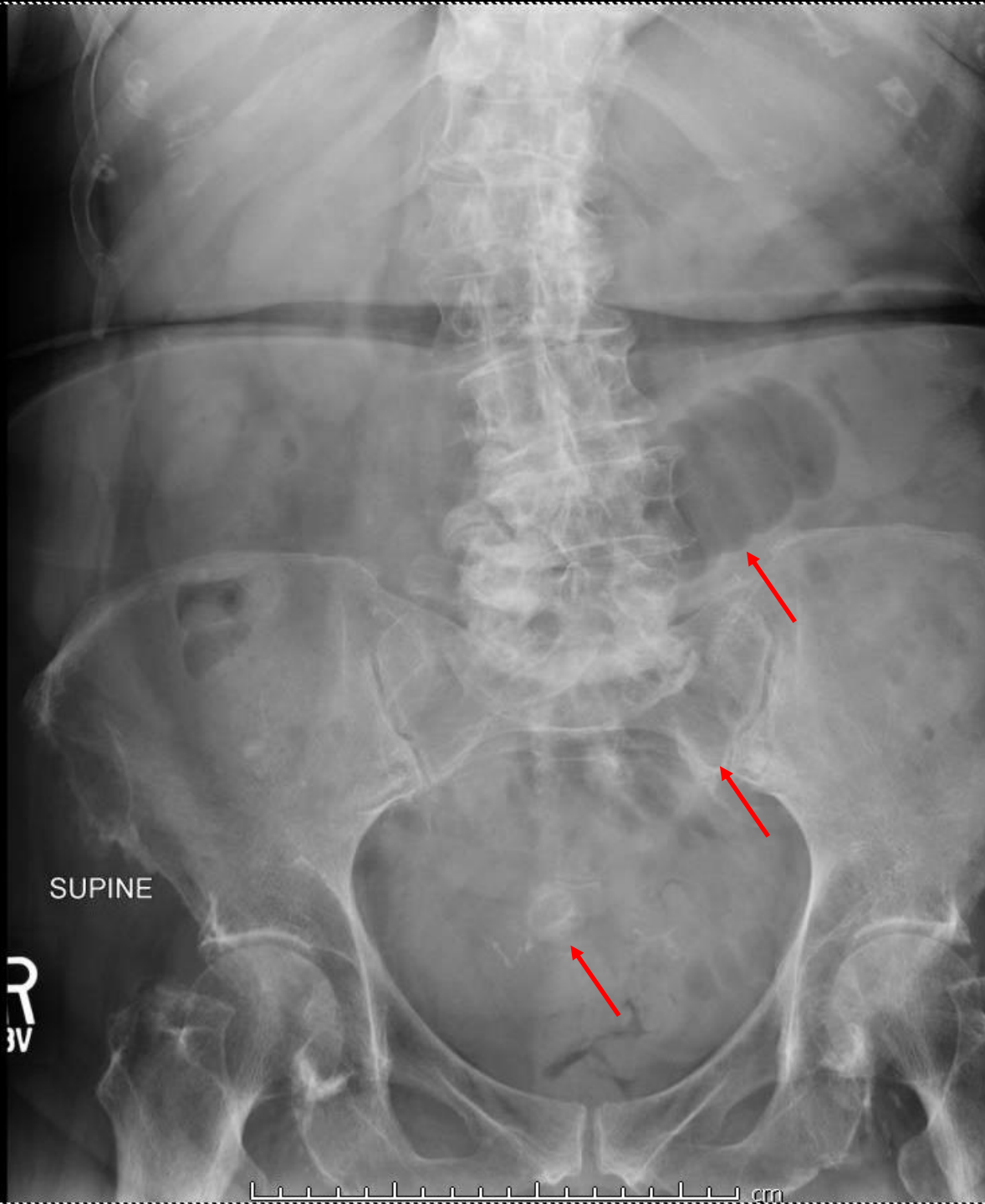
91 yo F with PMHx of CAD, HTN, asthma, and uterine fibroids presents to urgent care with nausea/vomiting x 2 days



SUPINE

R
W

cm



SUPINE

R
W



Impression: possible localized ileus.

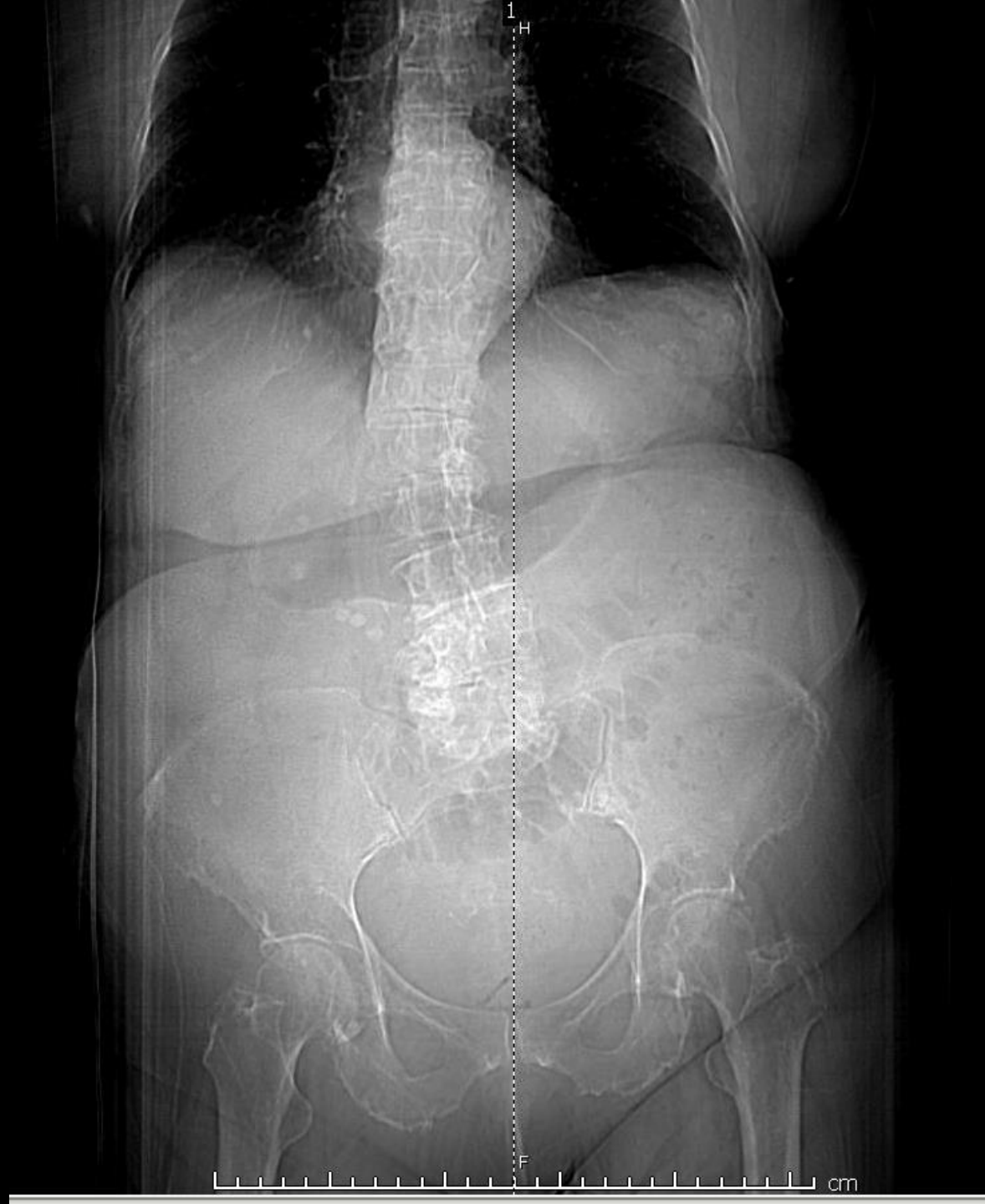The patient was sent home with Reglan and return precautions.

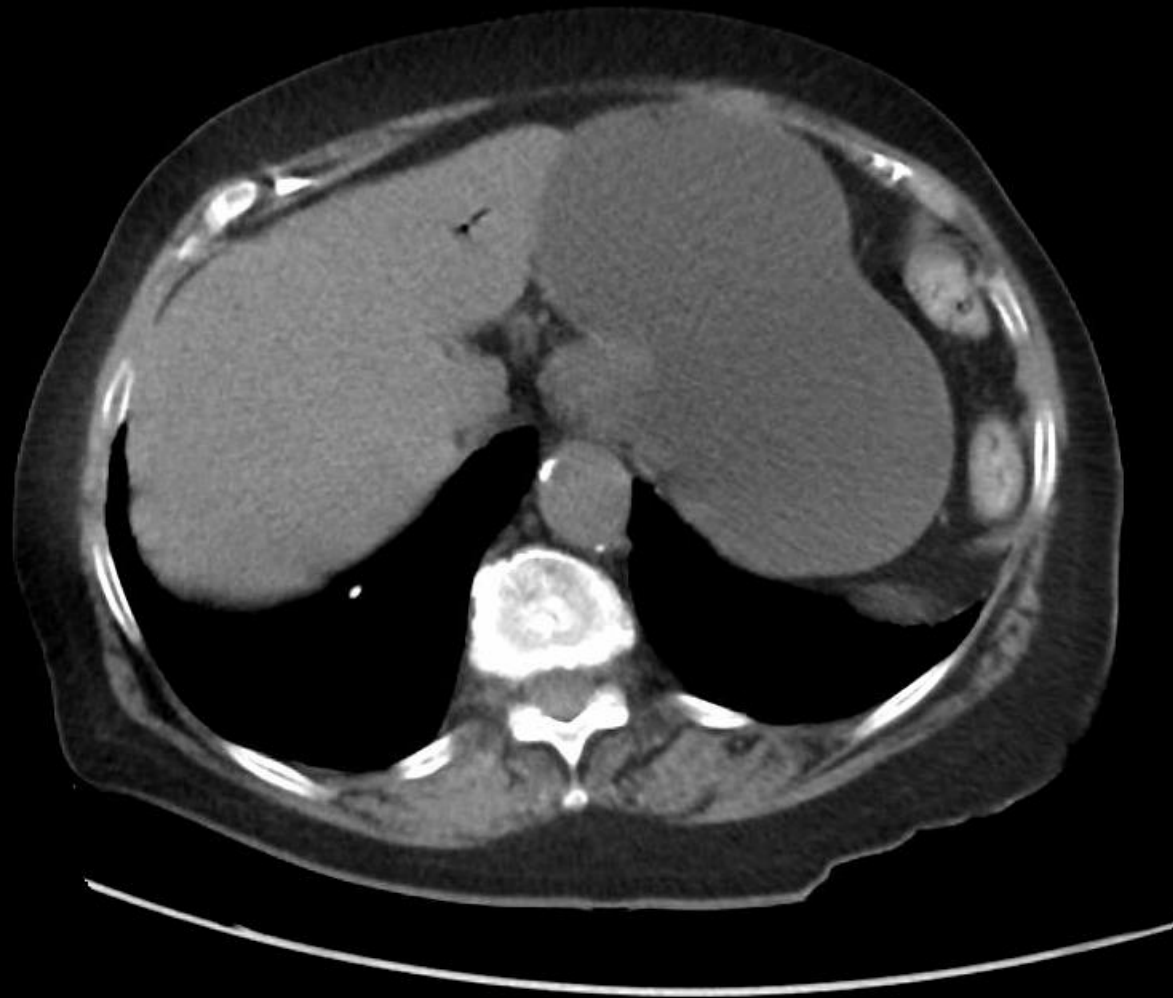
She had recurrent projectile emesis overnight. The next morning, she presented to the ED.

Vitals: wnl

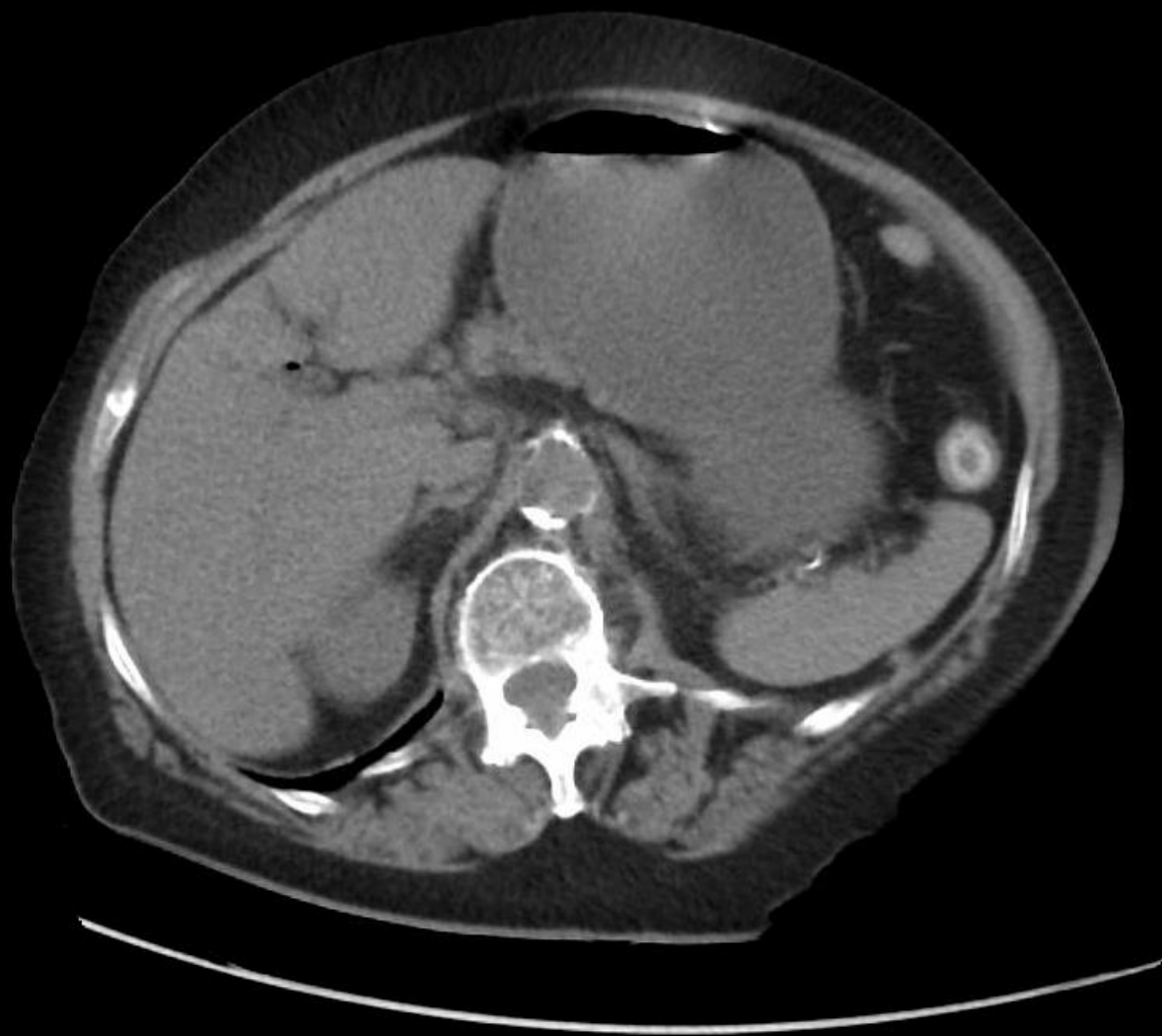
Labs: WBC 17, bicarb 21, lactate 3.2, creatinine 1.99 (baseline 0.8), LFTs wnl

What imaging would you order?





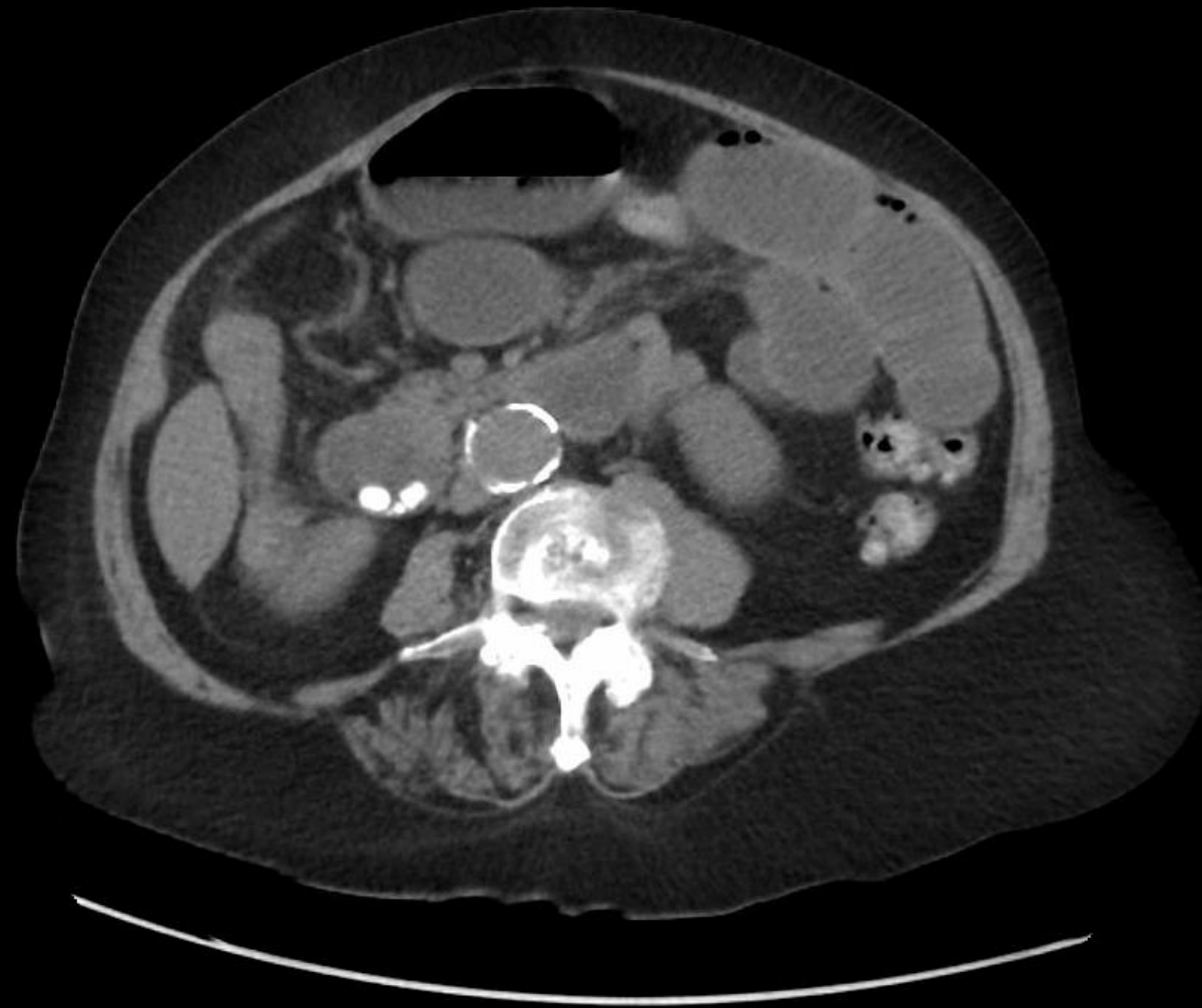
A



P

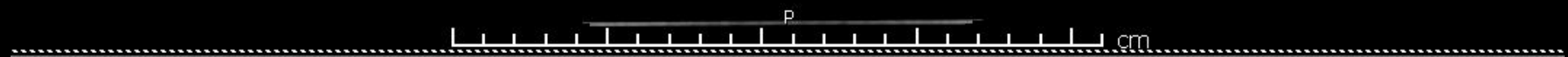
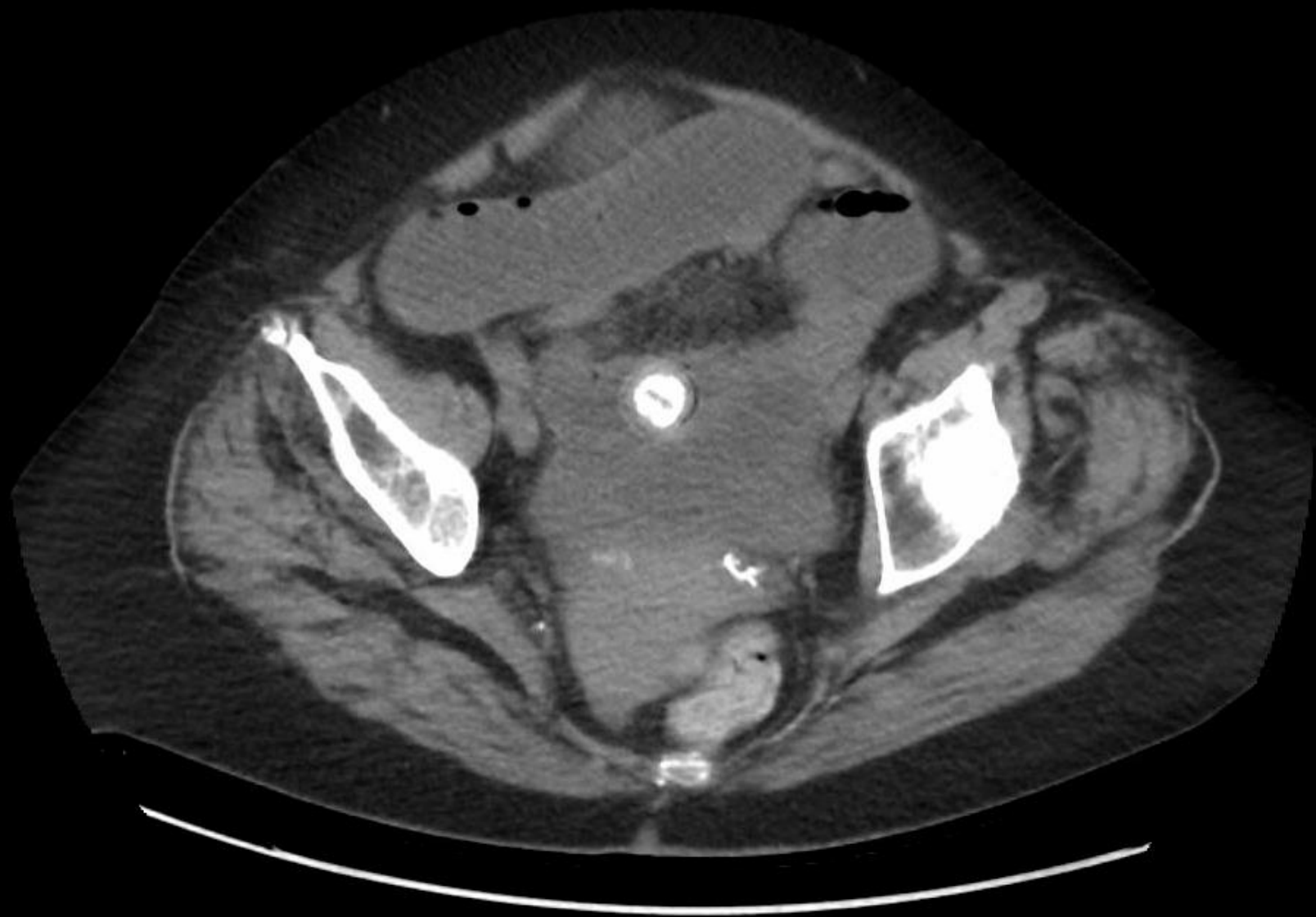

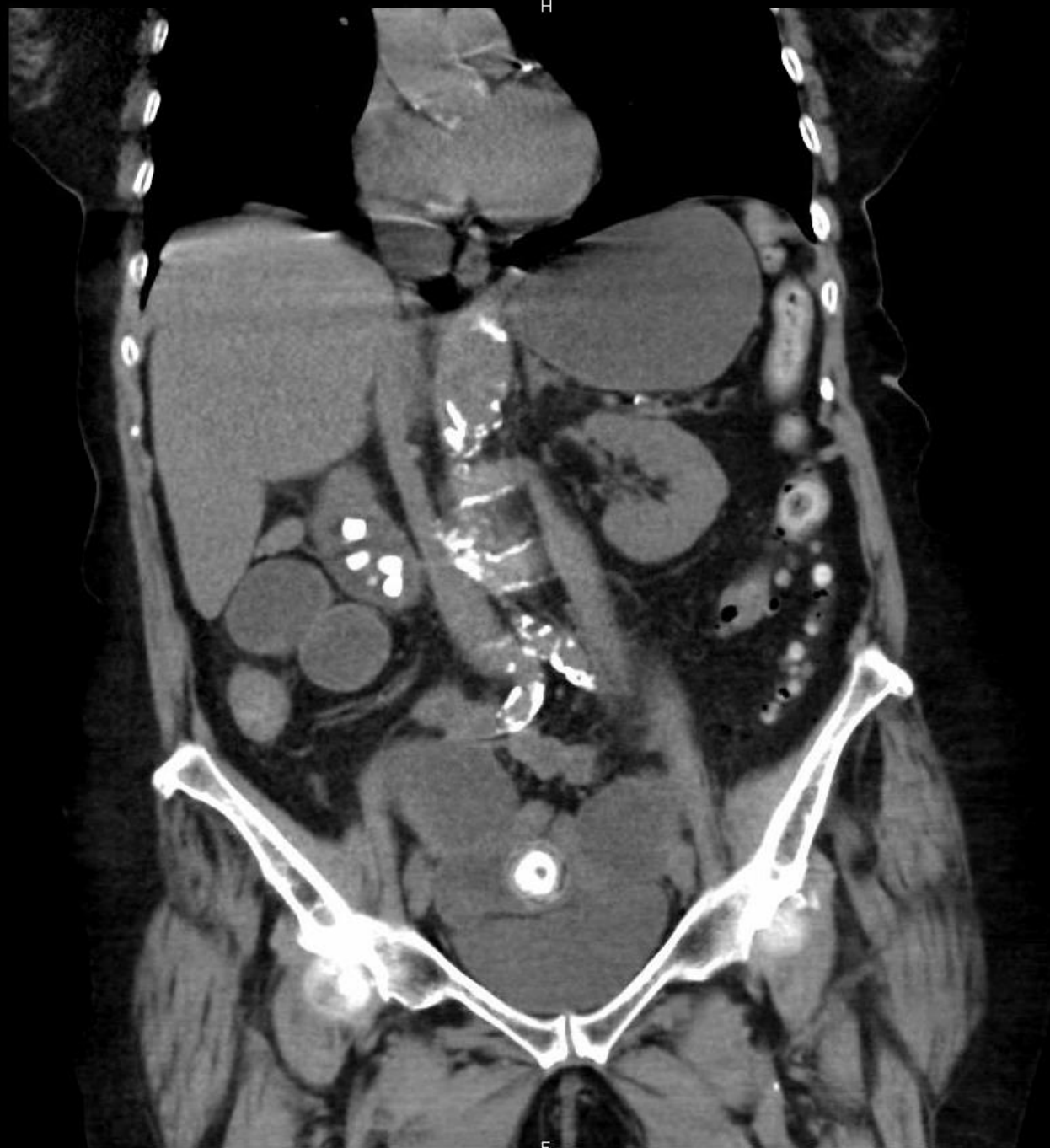
A

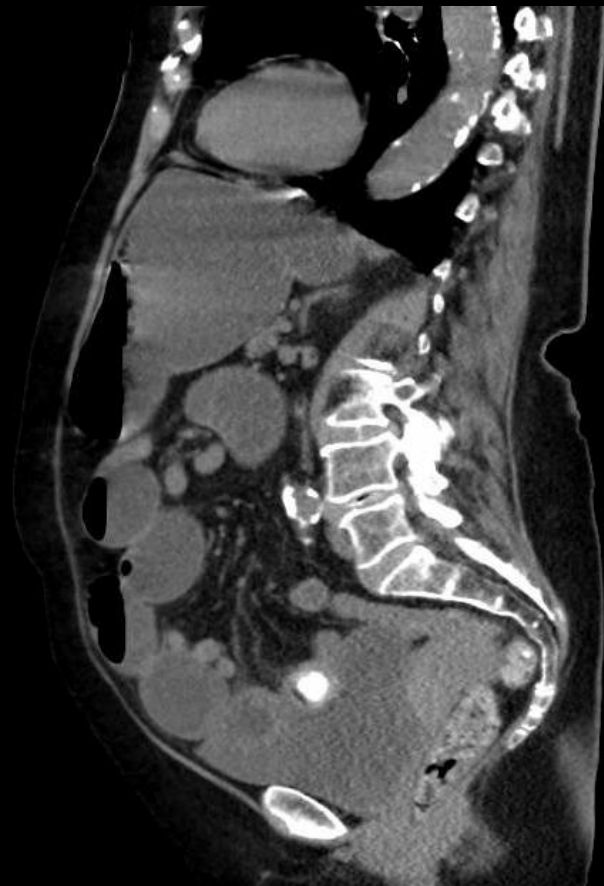
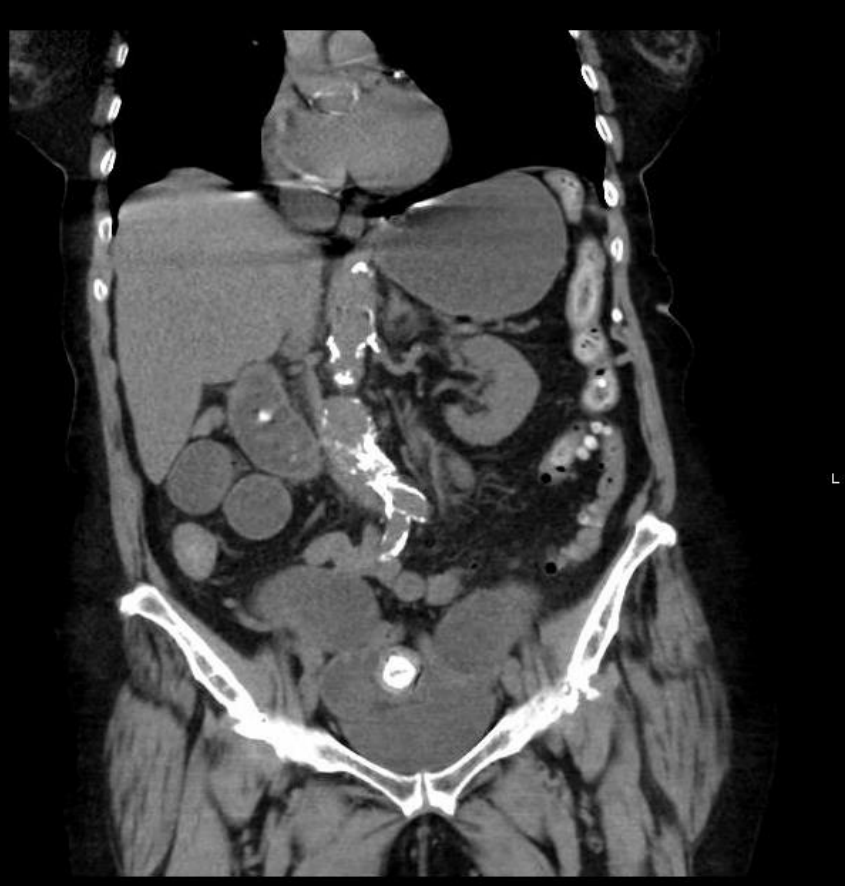
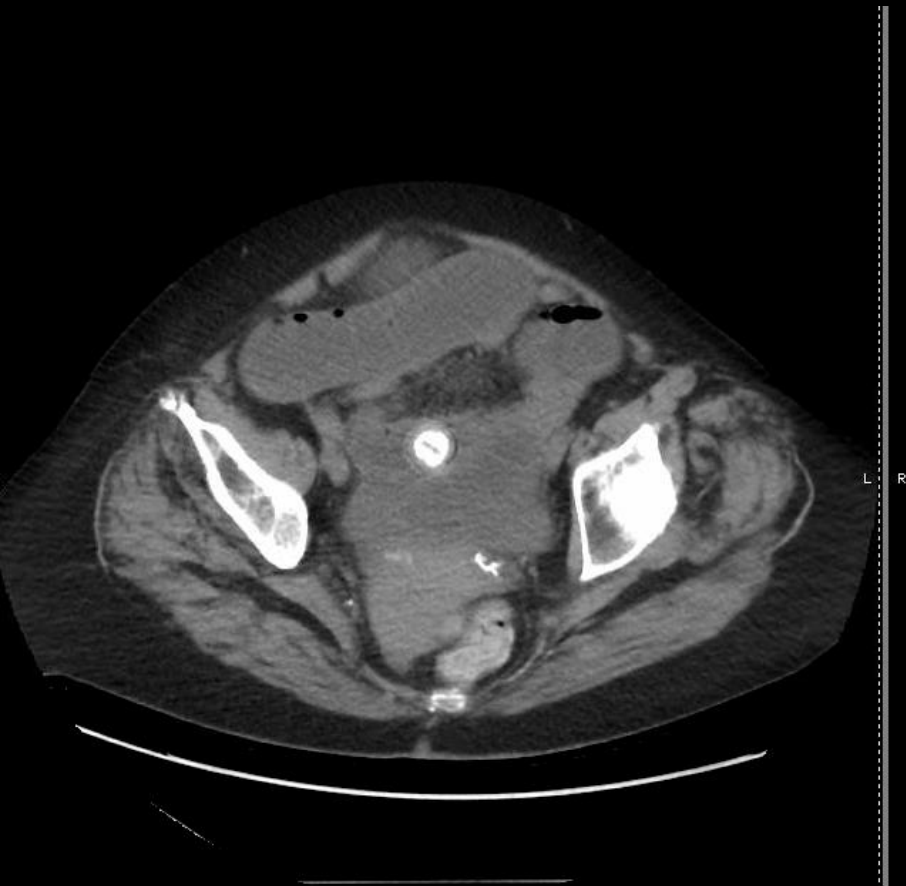P









Gallstone ileus

Gallstone passes into the bowel and becomes impacted, causing bowel obstruction

Mechanism

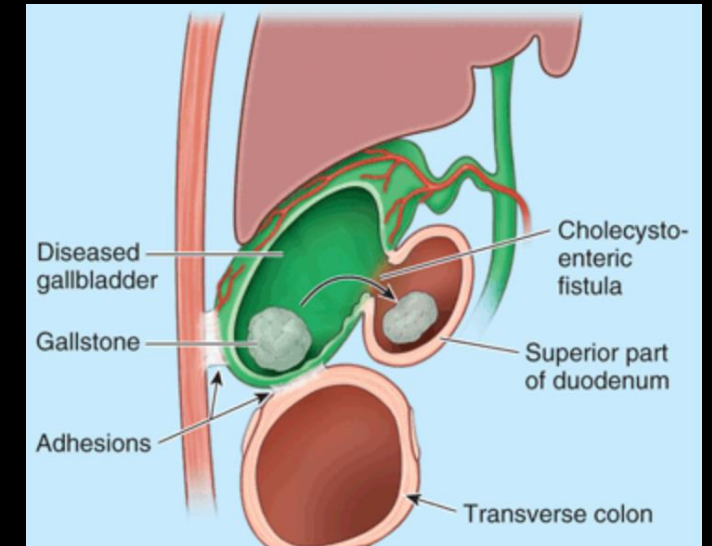
- Recurrent cholecystitis → adhesions b/w gallbladder and small bowel → biliary-enteric fistula
- Can also occur after ERCP with sphincterotomy
- Ileus is a misnomer as the obstruction is mechanical, not functional

Epidemiology

- <1% of small bowel obstructions
- More common in elderly, female patients with comorbidities
- Also more common on board exams!

Presentation

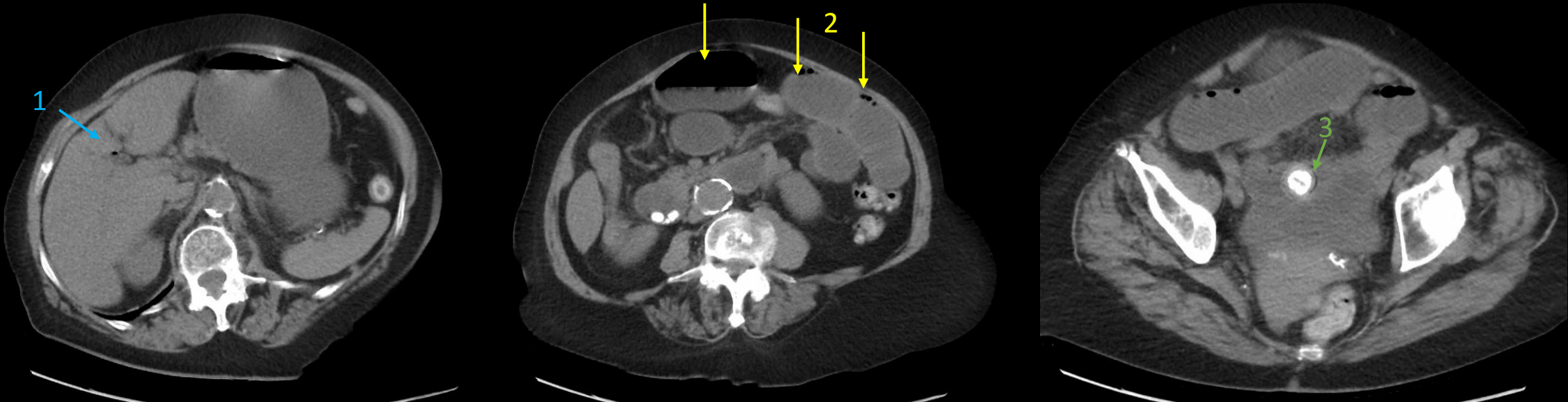
- “Tumbling obstruction” → episodic subacute symptoms of obstruction
- Abdominal pain, nausea/vomiting, distention



Gallstone ileus

Diagnosis

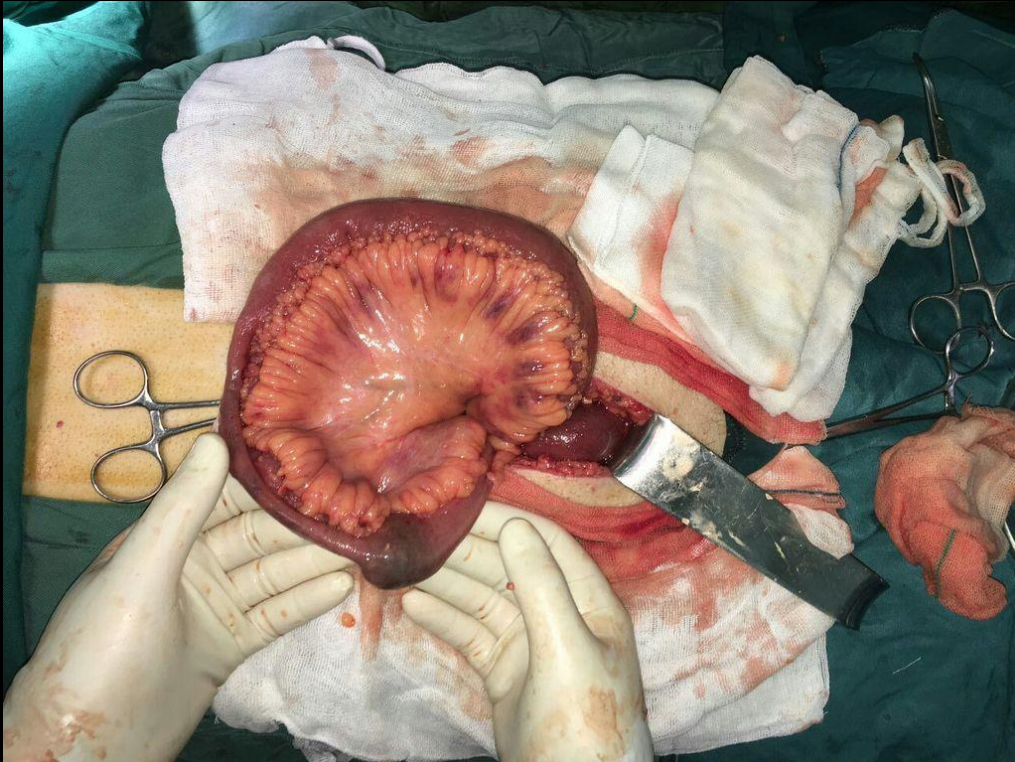
- Abdominal CT is imaging modality of choice
- **Rigler triad**
 1. Pneumobilia
 2. Small bowel obstruction
 3. Obstructing ectopic gallstone



Gallstone ileus

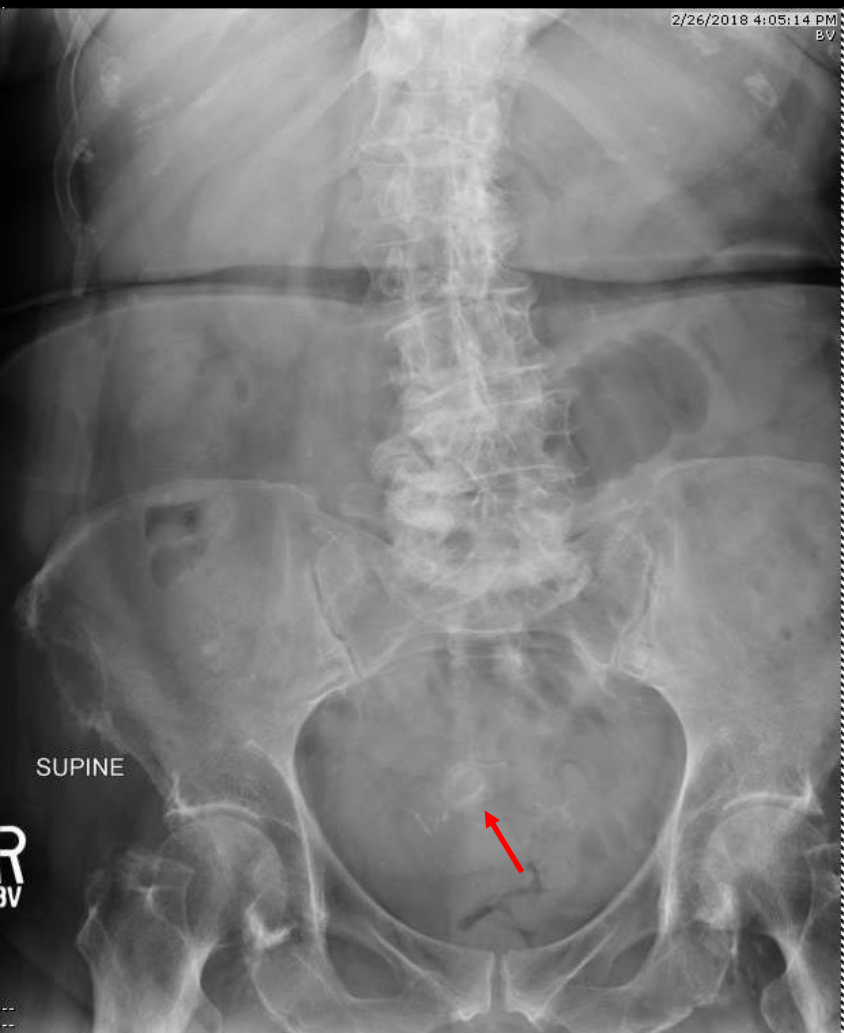Treatment

- Surgery: stone removal, with possible cholecystectomy and biliary-enteric fistula closure
- Mortality rate 5-25%

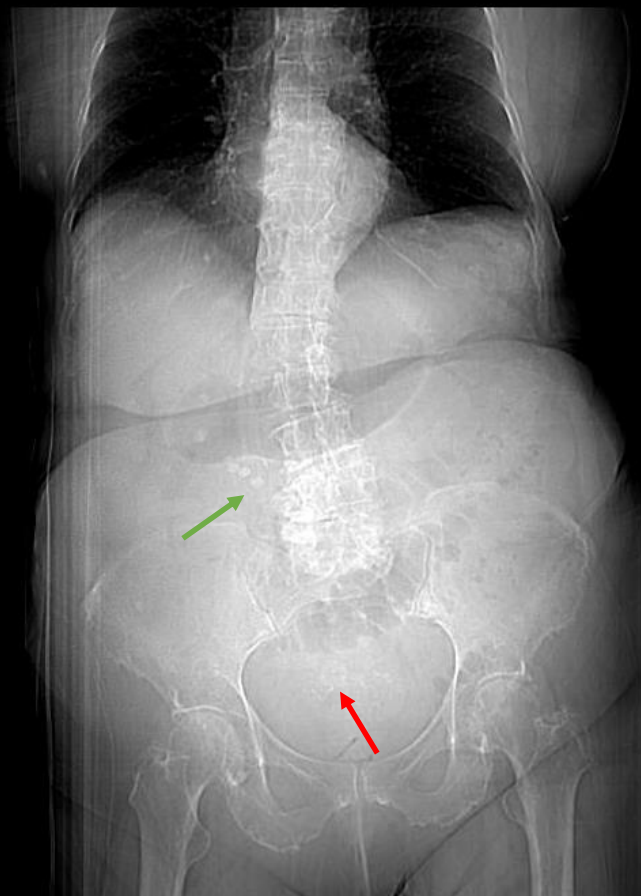


Our patient was taken to the OR for exploratory laparotomy and removal of stone, which was found lodged in the distal jejunum with a clear transition point.

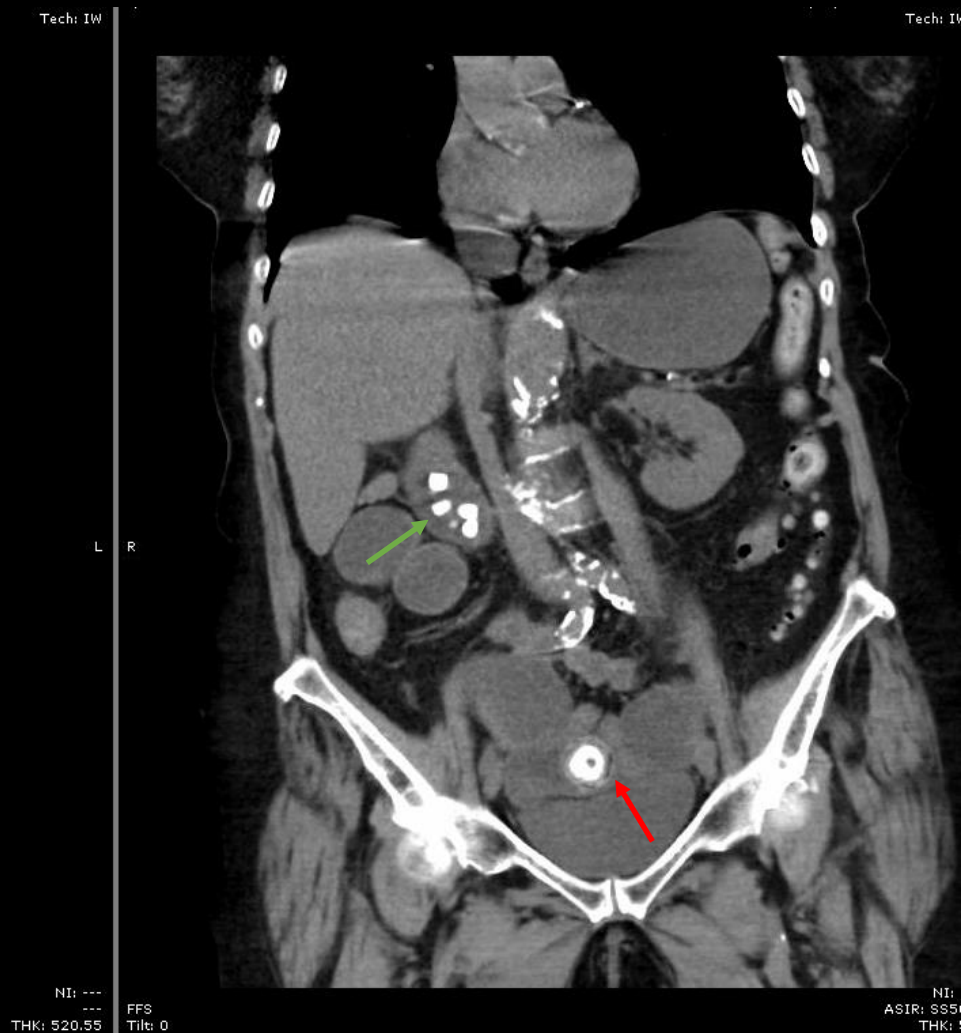
She recovered well and was discharged to short-term rehab.



AXR from urgent care



Scout



CT

References

Chuah PS, Curtis J, Misra N, et al. Pictorial review: the pearls and pitfalls of the radiological manifestations of gallstone ileus. *Abdom Radiol*. 2017;42(2):1169-75.

Keaveny AP, Afdhal NH, Bowers S. Gallstone ileus. UpToDate. www.uptodate.com. Accessed 3/21/2018.

Hartung MP, Gaillard AF. Gallstone ileus. Radiopaedia. www.radiopaedia.org. Accessed 3/21/2018.